

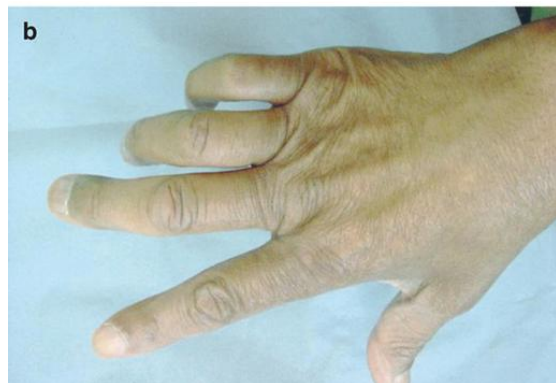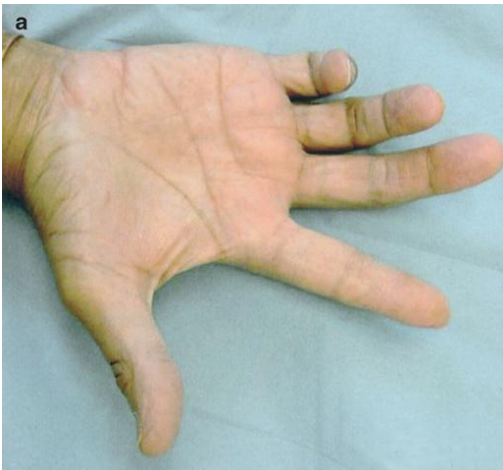
LEARNING OBJECTIVES

At the end of this session the students should be able to:

- Know the normal structures of the elbow region
- Know the neurovascular relations of the elbow joint
- Know the common injury patterns of this region
- Differentiate the various neurovascular injuries at the elbow

CASE SCENARIO

A 30 years old laborer, who has a history of knife injury to his right elbow four weeks back, came to OPD (out patient department) with complaints of weakness and deformity of his right hand. On examination he has wasting of hypothenar muscles, guttering of dorsum of the hand, flexed interphalangeal and hyperextended metacarpophalangeal joints of medial two fingers. There is also loss of sensation of the medial third of the palm and medial one and a half fingers.



Questions:

- 1. What is this deformity of hand commonly called?**
- 2. What is cause of these abnormal findings?**
- 3. What is the most probable site of injury to ulnar nerve?**
- 4. What are other sites at which this nerve can be injured?**
- 5. How do you differentiate injury at elbow from other sites of injury?**
- 6. What other mechanisms may involve ulnar nerve at this site besides direct trauma?**
- 7. What other signs you can predict to find on examination?**
- 8. How do you differentiate from median neuropathy?**
- 9. What investigations should be ordered to confirm diagnosis?**